

## Drop Foot; A Case of An Unexpected Complication After Coronary- Artery Bypass Surgery

Dr. Kadir Çeviker<sup>1</sup>, Merve Güblü<sup>2</sup>, Dr. Dinçer Uysal<sup>1</sup>, Dr. Altay Nihat Acar<sup>1</sup>,  
Assoc.Prof.Dr. Hasan R. Koyuncuoğlu<sup>3</sup>, Prof. Turhan Yavuz<sup>1</sup>

<sup>1</sup> Department of Cardiovascular Surgery, Süleyman Demirel University Medical Faculty, Isparta, Turkey

<sup>2</sup> Medical Student, Süleyman Demirel University Medical Faculty, Isparta, Turkey

<sup>3</sup> Department of Neurology, Süleyman Demirel University, Medical Faculty, Isparta, Turkey

Received 12.January.2017; Accepted 17.January.2017

Published with open access at [www.smyrnamed.com](http://www.smyrnamed.com)

**ABSTRACT:** Drop foot following coronary artery bypass graft surgery (CABG) is a very rare entity with the pathogenesis elaborated. Drop foot which occurs after CABG can arise from various musculoskeletal or neurologic etiologies in patients with risk factors such as previously neuropathies, hypertension, hypotension, hyperlipidemia, anemia and Diabetes Mellitus. Postoperative neurologic causes of drop foot include mononeuropathies of the deep peroneal nerve, the common peroneal nerve, or the sciatic nerve. This article presents clinical and radiological findings of nerve root palsy due to compression of a lumbar disc herniation in a 68-year-old patient admitted with drop foot following CABG.

**Keywords:** Coronary artery bypass surgery; complication; drop foot; peripheral neuropathy; lumbar disc hernia.

### I. INTRODUCTION

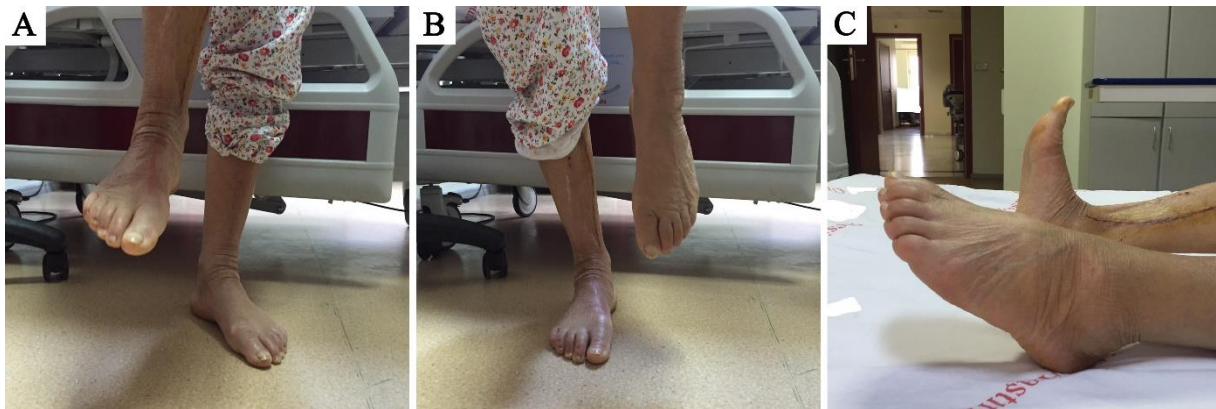Although cardiac surgery is the necessity for some of the patients with ischemic heart disease, severe complications may occur in the postoperative period. Perioperative (within 48 h) peripheral nerve injuries following a cardiac surgical procedure is a well-known clinical problem usually attributed to the mechanical forces of stretch, compression, contusion or transection traction, laceration, entrapment, hypoxia (1,2). Although peripheral neuropathy is a very rare complication of cardiac surgery with an incidence of 0.03%, these neuropathies may result in prolonged patient impairments (3). Drop foot is one of the result of peripheral neuropathy and it is less frequent and usually less severe than other complications; but also quite serious obstacle for patients (1). While, predisposing systemic conditions include hypotension in patient with previously hypertension (HT), diabetes mellitus (DM), hypercholesterolemia, anemia and infection, may cause a commotion to find the reason of the complication and to treat the neuropathy (3). In this report, it has been presented a patient with drop foot following an uneventful cardiac surgery and has been discussed the management of treatment.

## II. CASE

A 68 year-old, 54 kg, 153 cm, female with a history of chest pain was admitted for coronary artery bypass surgery. Routine preoperative arrangement for surgery was done and blood tests, electrocardiogram, echocardiogram, x-ray and systemic examinations were within normal range. Surgery was performed with the standard supine position, standard technique of median sternotomy and saphena vein graft preparation, and the standard on-pump technique. During extracorporeal circulation, the systolic blood pressure was maintained between 50-70 mmhg; hemoglobin and hematocrit levels were maintained above 8 g/dL and 27 %, respectively. Intraoperative heparinization was managed as standard procedure and the activated clotting time was maintained above 480 seconds. There was no calcified plaque that may cause embolism during surgery at the aortic cannulation and proximal bypass sites, and care was taken to avoid embolism of air, lipid and other particles. No extraneous blood was used during or after the operation. Total surgery, cardiopulmonary bypass and cross clamp times were 190, 76 and 43 minutes, respectively. Hemoglobin and hematocrit levels were 12 g/dl and 34% respectively after the operation. Following an uneventful surgery, the patient was monitored in the intensive care unit (ICU). Around 5 h after the surgery, the patient was extubated without any surgical complication and was at a hemodynamically stable situation. However, the patient was observed to be “numbness and pain in left foot” by the ICU nurse during routine examination 11 h after the surgery.

On neurologic examination, the lower limbs had normal tone bilaterally, including the ankles. On the right side, the power of right dorsiflexion was 5/5, contraction of extensor hallucis longus was 5/5, and plantar flexion was 5/5. On the left side, the power of right dorsiflexion was 1/5, contraction of extensor hallucis longus was 1/5, and plantar flexion was 4/5. The power in the other muscle groups in the lower limbs was normal (figure 1).

**Figure 1.** The power in the other muscle groups in the lower limbs

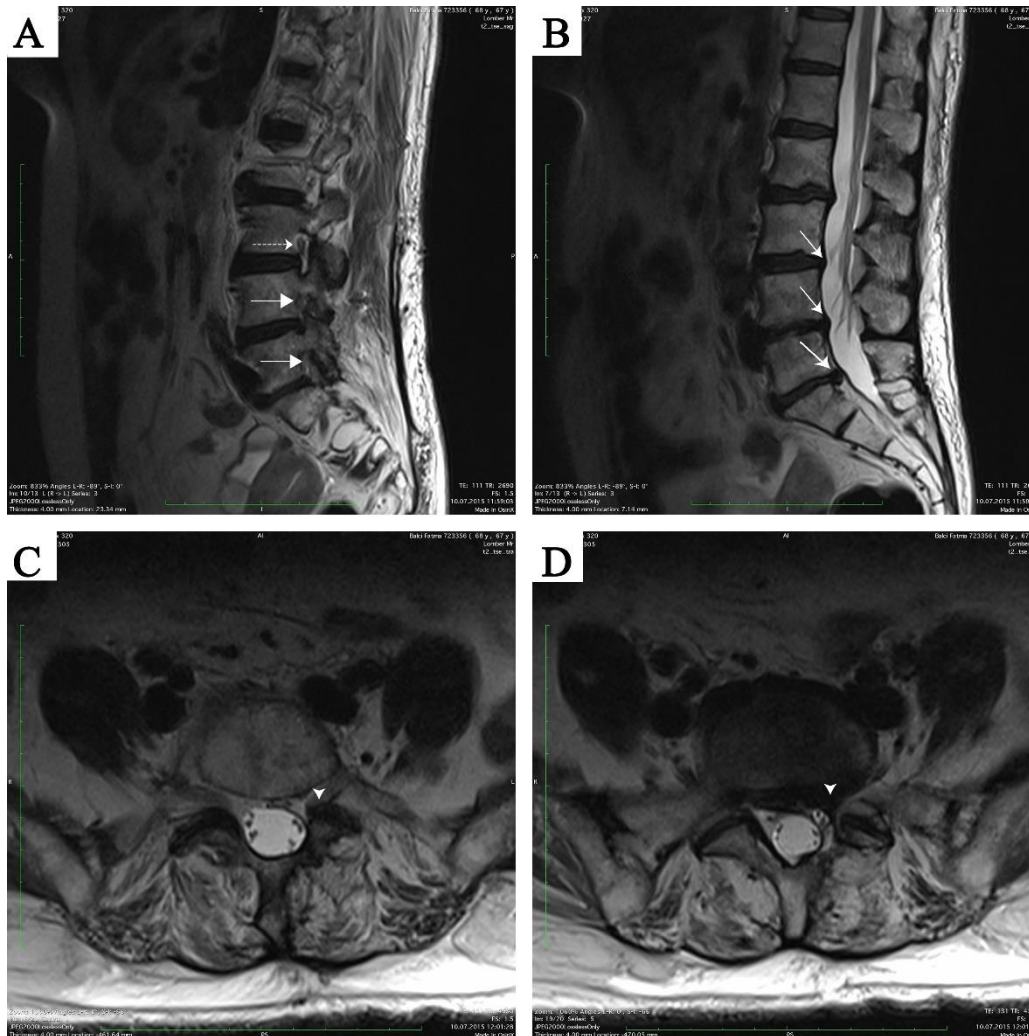


The knee reflex was normal bilaterally. The ankle reflex was mildly brisk on the left side and normal on the right side. There were no beats of clonus bilaterally. Sensation to light touch was decreased on the left side, normal on the right side.

Electrolyte levels were within normal limits (sodium 142 mEq/L, potassium 4.3 mEq/L, chloride 104 mEq/L). The blood glucose level was 102 mg/dl, urea was slightly elevated at 11.8 mmol/L, and creatinine was 107 mmol/L. Triplex ultrasonography excluded arterial thromboembolic event and deep vein thrombosis. Electroneuromyography revealed a severe sensomotoric axonal lesion of the left sciatic nerve: an absence of evoked response in left tibial, left sural and the right common peroneal nerve; an absence of sensory conduction velocities and action potentials amplitudes on the left lower limb. Magnetic resonance imaging (MRI) neurography were performed and the results

indicated a L4-L5 left paramedian dural sac indenting protrusion and a L5-S1 left foramina posterior protrusion has been examined and left neural foremen narrowing from inferior segment with a high T2 signal (figure 2).

**Figure 2.** Magnetic resonance imaging (MRI) neurography



Other neurological examinations were all within normal ranges. The patient was treated with intravenous methylprednisolone at a dose of 160 mg/day in four doses. She was monitored one more day in the ICU and discharged to the general ward at postoperative third day. The patient was discharged and allowed to go home after seven days with recommendations of exercises for drop foot. After two weeks she was examined at the clinic and no improvement on the drop foot was noticed. The patient was fitted with an ankle foot orthosis, given medications for neuropathic pain, and eventually regained slow but not completely strength after 6 months.

### **III. DISCUSSION**

Postoperative peripheral neuropathy should be occurred as the results of several different mechanisms as compression, traction, laceration, entrapment and hypoxia (3). Certain metabolic failures may increase the risk of neuropathic complications as well (4).

In our case, there were no metabolic failures or concomitant disease except lumbar disc hernia (3 years) and patient's perioperative vital parameters were in normal limits. Therefore the patient has an average postoperative stay in ICU (<96 hours). It was learned in her history that she had a lumbar disc surgery two years ago and MR imaging which was taken after the drop foot complication, revealed that the herniated discs was found to be at the critical level. Lumbosacral plexopathy, lumbar radiculopathy, motor neuron disease, or parasagittal cortical or subcortical cerebral lesions also can manifest as foot drop (5). Neurologic causes of foot drop include mononeuropathies of the deep peroneal nerve, the common peroneal nerve, or the sciatic nerve. These lesions can be differentiated by means of clinical and electrodiagnostic examinations. Peroneal nerve palsy is the most frequently seen mono-neuropathy type that may be occur following CABG (1). It may occur when compression or traction around the knee since it passes lateral to the surgical neck of the fibula. Supine position may have a part in this damage (1).

In addition, low perfusion pressure and hemodilution during the CABG may induce further hypoxia of the nerves (1). But in these cases the drop foot appears reversible and usually does not arise on one side. L4-L5 radiculopathy is the most common recognized cause of foot drop, usually caused by herniated nucleus pulposus or foramina stenosis (2). Weak ankle dorsiflexion, foot eversion, foot inversion, hip internal rotation / abduction indicate L5 radiculopathy. Unfortunately, the mechanism of nerve injury is unclear in the majority of cases associated with surgery and general anesthesia. Prolonged operation and immobilization in the intensive care unit at supine position may trigger the nerve damage especially in patients with previously history of critical disc herniation or any surgery to decompress the nerve (discectomy, neural repair, etc.) (6). Because of paralysis of all muscles during operation may become nerve roots more prone to be damaged at lumbar region. And also nerve compression in the vertebra can block the flow of nutrients to the nerves in the lower limb, making it more susceptible to injury. This is called the double crush syndrome (7). In this patient, L4-5 and L5-S1 radiculopathy, prolonged surgery and ICU stay in supine position may be the suspected reasons for the drop foot.

### **IV. CONCLUSION**

In the present report, although all necessary standardized diagnostic studies such as laboratory tests, radiography and examinations have been underwent preoperatively, it is not envisaged that drop foot may occur after surgery. On the other hand, although the patient had immediate treatment modalities such as ankle foot orthosis and medications, relief of symptoms and normalization of her gait can't be provided and these patients may need of more intensive and expensive treatment modalities such as osteopathic manipulative treatment, or invasive treatments (nerve root blocks, spinal decompression, tendon transposition, etc.) (5).

### **V. ACKNOWLEDGEMENTS**

Full verbal and written consent has been obtained from the patient for submission of this manuscript for publication. All authors declare no funding was required for the writing and submission of the manuscript.

### **REFERENCES**

1. Durmaz B, Atamaz F, On A: Bilateral common peroneal nerve palsy following cardiac surgery. *Anatol J Cardiol* 2008;8(4):313-4.

2. Westhout FD, Paré LS, Linskey ME. Central causes of foot drop: rare and underappreciated differential diagnoses. *The Journal of Spinal Cord Medicine* 2007;30(1):62–6.
3. Staff NP, Engelstad J, Klein CJ, et al. Post-surgical inflammatory neuropathy. *Brain* 2010;133(10):2866-80.
4. Azarfarin R, Ashouri N, Totonchi Z, et al. Factors Influencing Prolonged ICU Stay After Open Heart Surgery. *Research in Cardiovascular Medicine* 2014;3(4):1–4.
5. Stewart JD. Foot drop: where, why and what to do? *Practical Neurology* 2008;8(3):158-69.
6. Pereira CU, Lepski G, Jose B, et al. Foot drop following lumbar disc herniation. *Rev Chil Neurocirugia* 2014;40: 34–6.
7. Subhawong TK, Wang KC, Thawait SK, et al. High resolution imaging of tunnels by magnetic resonance neurography. *Skeletal Radiology* 2012;41(1):15-31.